



CASE REPORT

Anomalous origin of right coronary artery from the pulmonary artery: an incidental finding on cardiac computed tomography in a patient presenting with dyspnea

Rachel Anne Xuereb,¹ Sara Xuereb,² Kentaro Yamagata,² Robert George Xuereb²

¹Department of Medicine, and ²Department of Cardiology, Mater Dei Hospital, Msida, Malta

Abstract

Anomalous right coronary artery originating from the pulmonary artery (ARCAPA) is rare with an incidence of 0.002%. It usually presents in adulthood with symptoms of angina and is often associated with other congenital anomalies. We report a case of ARCAPA, that was diagnosed on investigation of dyspnea on exertion.

Key words coronary artery abnormalities, anomalous right coronary artery originating from the pulmonary artery, cardiac computed tomography, congenital.

Received: 7 November 2023; Accepted: 20 November 2023.

*Correspondence to: Rachel Anne Xuereb, Mater Dei Hospital, Triq Dun Karm, Msida, MSD 2090, Malta. E-mail: rachel.xuereb94@gmail.com

Case report

A 75-year-old Caucasian female, with a history of atrial fibrillation, hypertension and chronic kidney disease, presented with dyspnea on minimal exertion and paroxysmal nocturnal dyspnea. She denied chest pain, palpitations or syncope. Transthoracic echocardiography (TTE) showed severe tricuspid regurgitation and evidence of diastolic dysfunction with mildly raised pulmonary pressure. Both atria and the right ventricle were dilated. Left ventricular systolic function was normal with an ejection fraction of 63%. She was referred for cardiac computed tomography (CT) for further assessment. The cardiac CT showed a large, tortuous right coronary artery (RCA) originating from the anterior cusp of the main pulmonary artery (PA), passing anterior to the aortic root along the anterior atrioventricular groove (Figures 1 and 2). This is known as ARCAPA. The origin of the left coronary artery (LCA) is normal. Mild stenosis at the proximal left anterior descending artery (LAD) was present. A conservative approach to management is being followed with yearly monitoring to assess symptoms and echocardiography to assess valvular pathology.

Discussion

In typical anatomy, the RCA arises from the right aortic sinus of Valsalva and the LCA arises from the left aortic sinus of Valsalva.¹ Anomalous origin of coronary arteries from the contralateral sinus of Valsalva are more common compared to anomalous origin of the right or left coronary artery from the PA.¹ ARCAPA is a rare congenital coronary anomaly with an incidence of 0.002% and represents 0.12% of coronary anomalies.² One-third are associated with other congenital heart defects,³ most commonly aorto-pulmonary window in 11%, ventricular septal defects in 6% and atrial septal defects in 5%.³ Less than 15% are diagnosed at younger than 1 year of age.⁴ The mode of presentation ranges from asymptomatic cases to sudden cardiac death.⁴ In adulthood most patients with ARCAPA are symptomatic, the most common symptom being angina in 22% followed by dyspnea in 17%.⁵ ARCAPA has led to cardiac arrest in 6% of reported cases.⁵ Those with a right dominant coronary circulation do not tolerate ARCAPA well, compared to those with a left dominant system.⁶ If collaterals develop between the LCA and RCA and the pulmonary pressure remains low, the LCA supplies oxygenated blood to the

entire heart and the patient may progress into adulthood without symptoms.⁶

Anomalous LCA originating from the pulmonary artery (ALCAPA) is also rare with an incidence of 0.008%.⁷ It usually presents in the first year of life with myocardial ischemia and untreated has a mortality rate greater than 85%.⁷ Few cases present in adulthood with arrhythmias, congestive heart failure, angina or sudden death.⁸ This difference in presentation between ARCAPA and ALCAPA is likely related to the smaller vascular distribution and decreased oxygen demands in the myocardium normally supplied by the RCA.⁸ Although initially

asymptomatic, these adult patients with single vessel coronary blood flow may become symptomatic due to atherosclerotic changes to the single coronary artery.⁸

In 40% of cases coronary artery anomalies are diagnosed on coronary angiography.⁹ TTE, cardiac CT and magnetic resonance imaging are more commonly being used as diagnostic modalities in these coronary anomalies.⁹ Treatment of ALCAPA and ARCAPA is indicated to prevent myocardial dysfunction in symptomatic individuals and to reduce the risk of sudden death in asymptomatic cases.¹⁰ Surgical treatment includes ligation of the anomalous artery or more commonly the anomalous coronary artery is repositioned to the aorta.¹⁰ When this is not possible an aortocoronary fistula, the Takeuchi repair, is carried out. Cardiac transplantation is the last resort.¹⁰

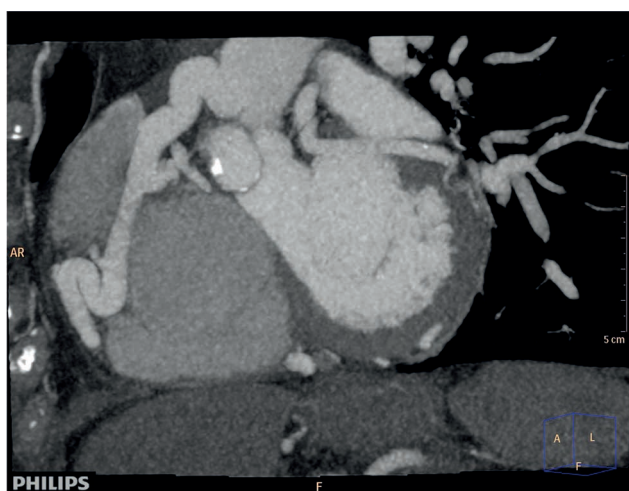

Figure 1. Cardiac computed tomography showing large, tortuous right coronary artery originating from the main pulmonary artery.

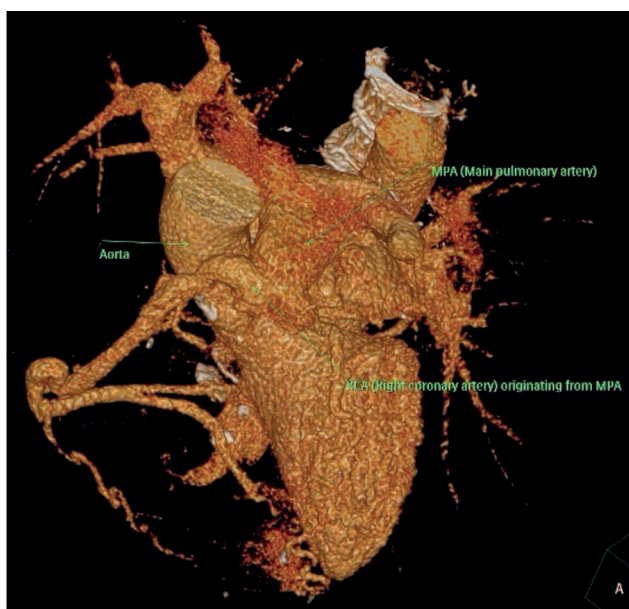


Figure 2. Reconstructed cardiac computed tomography showing right coronary artery originating from the main pulmonary artery.

Conclusions

ARCAPA is a rare congenital cardiac anomaly. It can be diagnosed on coronary angiography and other imaging techniques including cardiac CT. ARCAPA is important to recognize due to its long-term complications and potential for surgical repair.

Contributions

The authors contributed equally.

Conflict of interest

The authors declare no conflicts of interest.

Funding

None.

References

1. Lluri G, Aboulhosn J. Coronary arterial development: a review of normal and congenitally anomalous patterns. *Clin Cardiol* 2014;37:126-30.
2. Rawal H, Mehta SS. Anomalous right coronary artery originating from the pulmonary artery (ARCAPA): a systematic review of literature. *J Lung Health Dis* 2018;2:7-9.
3. Guenther T, Sherazee E, Wisneski A, Gustafson J, Wozniak C, Raff G. Anomalous origin of the right coronary artery from the pulmonary artery: a systematic review. *Ann Thorac Surg* 2020;110:1063-71.
4. Karimi M, Kirshbom P. Anomalous origins of coronary arteries from the pulmonary artery: a comprehensive review of literature and surgical options. *World J Pediatr Congenit Heart Surg* 2015;6:526-40.
5. Su JT, Krishnamurthy R, Chung T, Vick I, Kovalchin JP. Anomalous

- right coronary artery from the pulmonary artery: noninvasive diagnosis and serial evaluation. *J Cardiovasc Magn Reson* 2007;9:57-61.
6. Williams I, Gersony W, Hellenbrand W. Anomalous right coronary artery arising from the pulmonary artery: a report of 7 cases and a review of the literature. *Am Heart J* 2006;152:9-1004.
 7. Balakrishna P, Illovsky M, Al-Saghir Y, Minhas A. Anomalous origin of right coronary artery originating from the pulmonary trunk (ARCAPA): an incidental finding in a patient presenting with chest pain. *Cureus* 2017;9:1172.
 8. Yau JM, Singh R, Halpern EJ, Fischman D. Anomalous origin of the left coronary artery from the pulmonary artery in adults: a comprehensive review of 151 adult cases and a new diagnosis in a 53-year-old woman. *Clin Cardiol* 2011;34:204-10.
 9. Zhang C, Zhang H, Yan J, et al. Mid-term outcome for anomalous origin of the left coronary artery from the pulmonary artery. *Heart Lung Circ* 2020;29:766-71.
 10. Rajbanshi BG, Burkhart HM, Schaff HV, Daly RC, Phillips SD, Dearani JA. Surgical strategies for anomalous origin of coronary artery from pulmonary artery in adults. *J Thorac Cardiovasc Surg* 2014;148:220-4.